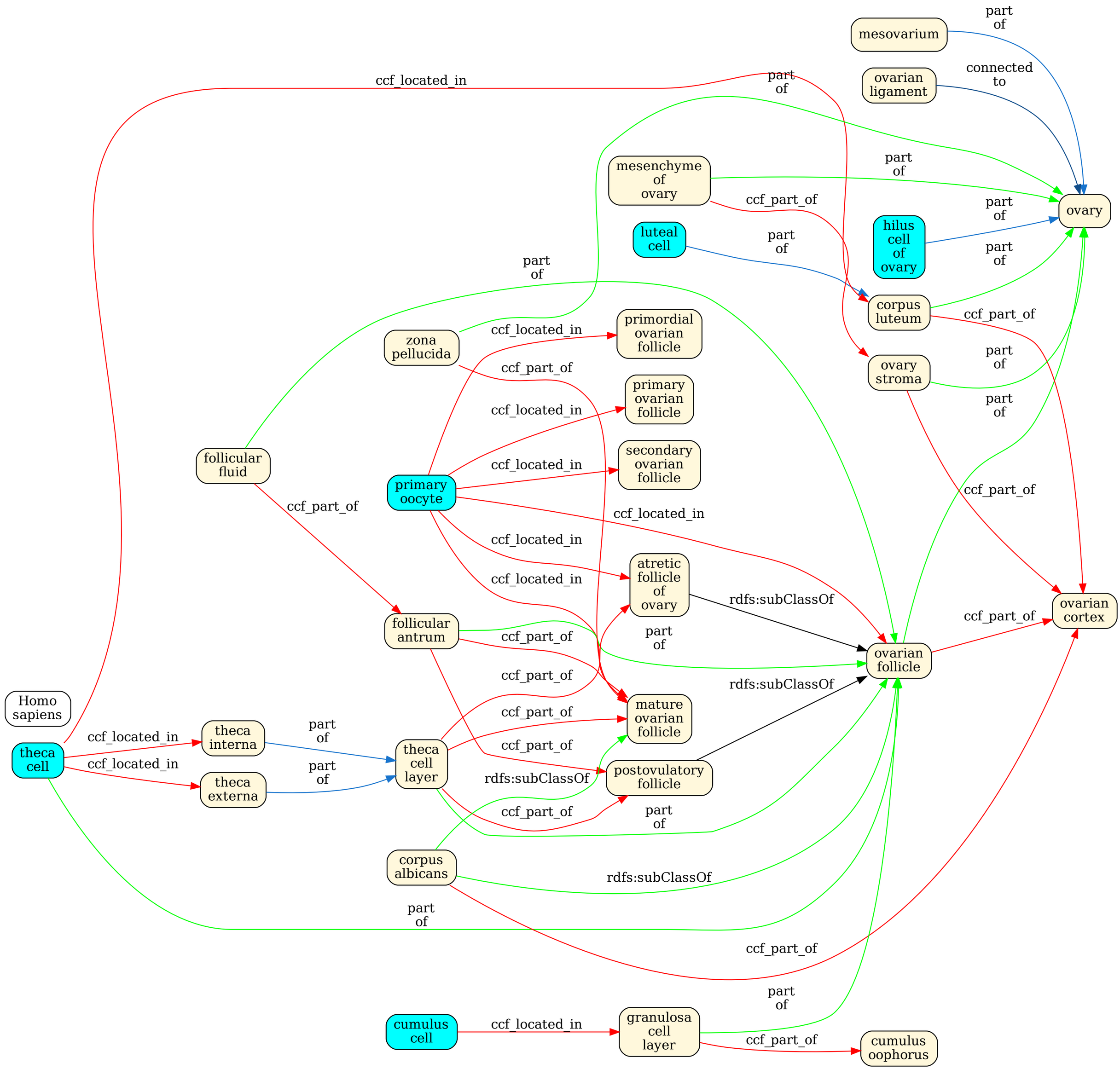
mesovarium
ovarian ligament
mesenchyme of ovary
ovary
luteal cell
hilus cell of ovary
corpus luteum
ovary stroma
zona pellucida
primordial ovarian follicle
primary ovarian follicle
secondary ovarian follicle
follicular fluid
primary oocyte
atretic follicle of ovary
follicular antrum
ovarian follicle
ovarian cortex
Homo sapiens
theca cell
theca interna
theca externa
theca cell layer
mature ovarian follicle
postovulatory follicle
corpus albicans
cumulus cell
granulosa cell layer
cumulus oophorus
ccf_located_in
ccf_part_of
part of
connected to
rdfs:subClassOf