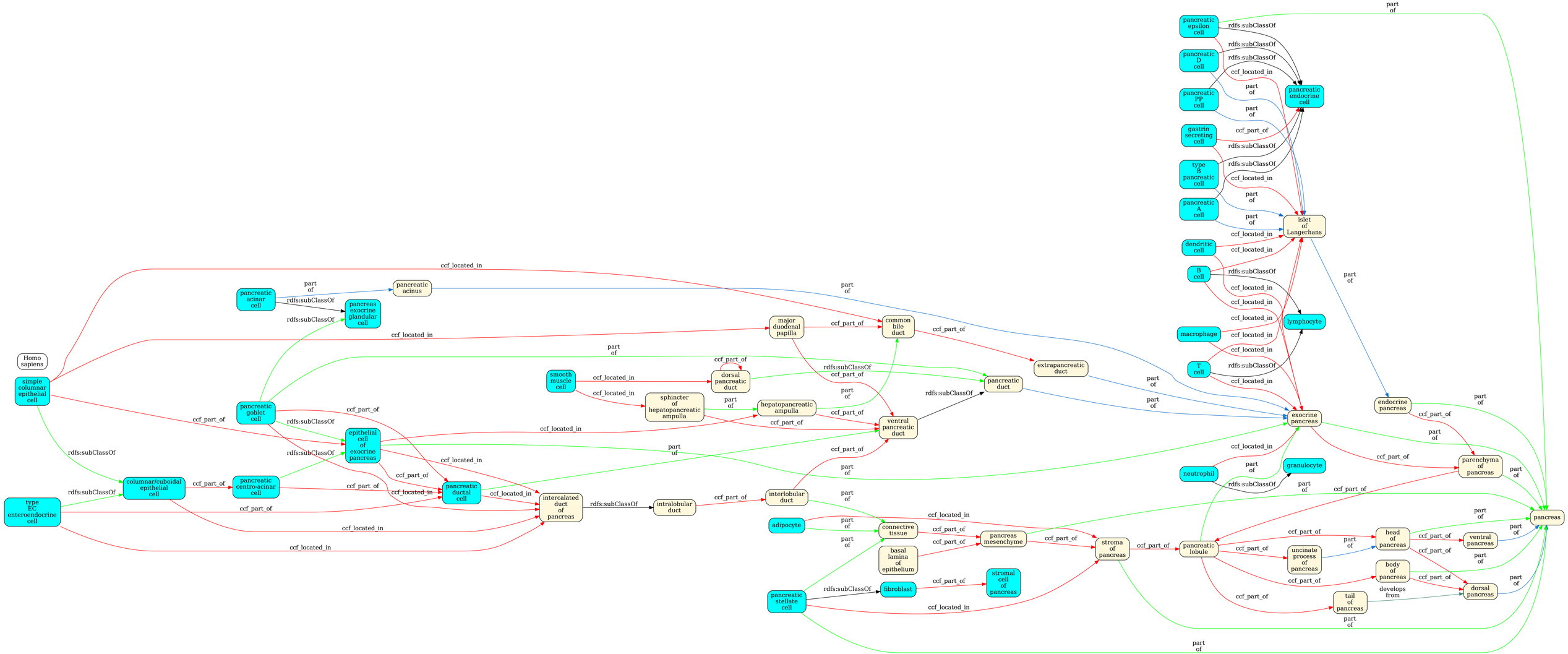
Homo sapiens
simple columnar epithelial cell
type EC enteroendocrine cell
columnar/cuboidal epithelial cell
pancreatic centro-acinar cell
pancreatic goblet cell
pancreatic acinar cell
pancreas exocrine glandular cell
pancreatic acinus
epithelial cell of exocrine pancreas
pancreatic ductal cell
intercalated duct of pancreas
intralobular duct
interlobular duct
major duodenal papilla
common bile duct
extrapancreatic duct
smooth muscle cell
dorsal pancreatic duct
sphincter of hepatopancreatic ampulla
hepatopancreatic ampulla
ventral pancreatic duct
pancreatic duct
adipocyte
connective tissue
basal lamina of epithelium
pancreas mesenchyme
stroma of pancreas
pancreatic stellate cell
fibroblast
stromal cell of pancreas
pancreatic lobule
head of pancreas
uncinate process of pancreas
body of pancreas
tail of pancreas
ventral pancreas
dorsal pancreas
pancreas
parenchyma of pancreas
exocrine pancreas
endocrine pancreas
islet of Langerhans
pancreatic endocrine cell
pancreatic epsilon cell
pancreatic D cell
pancreatic PP cell
gastrin secreting cell
type B pancreatic cell
pancreatic A cell
dendritic cell
B cell
lymphocyte
macrophage
T cell
neutrophil
granulocyte
ccf_located_in
ccf_part_of
rdfs:subClassOf
part of
develops from